

The Distribution of *Posthodiplostomum Cuticola* and *Rossicotrema Donicum* in *Scardinius Erythrophthalmus* and *Hypophthalmichthys Molitrix* Stemming from the Danube Delta

Cristiana Diaconescu¹, Laura Urdeş¹, Ştefan Diaconescu¹, Marius Hangan²

¹ Faculty of Animal Science, 011464-Bucharest, Marasti Bvd, 59, Romania

² Faculty of Biotechnologies, 011464-Bucharest, Marasti Bvd, 59, Romania

Abstract

We investigated the pathogenicity of *Posthodiplostomum cuticola* and *Rossicotrema donicum* digenean infestations within freshwater fish populations, in the Gorgova – Uzlina, Dunavat – Dranov and Razim – Sinoie natural complexes. The so-called “Black spot disease” caused by the metacercarial infestation was diagnosed in 5 out of 11 studied freshwater fish species: rudd (*Scardinius erythrophthalmus*), silver carp (*Hypophthalmichthys molitrix*), zarte (*Vimba vimba*), bream (*Abramis brama*) and European perch (*Perca fluviatilis*). The metacercariae were found mostly on the surface of the body (on fins, scales and skin), but also in the mouth, gills, eye sockets and even within the muscle, underneath the skin. Additionally, prevalence of the disease was estimated in rudd and silver carp during a 6-year study period. It resulted a maximum prevalence of 33.44% in the silver carp caught in Dunavat – Dranov (during the 5th year of the study) and a minimum prevalence of 22.81% in the rudd caught in Gorgova – Uzlina (during the 6th year of the study).

Keywords: Black spot disease, freshwater fish, pathogenicity, prevalence estimation

1. Introduction

Digenea (Phylum Platyhelminthes) are heteroxenous parasites (require more than one host to complete the life cycle). Adult stages infect the major groups of vertebrates. The majority of digeneans undergo their larval development in molluscs.

Apart from being hosts to adult stages, fish may be infected by the metacercarial larvae, which enter different tissues and form cysts. The most affected tissues are gills, fins, dermis, internal organs (i.e. heart, kidney), somatic muscle, eye and connective tissue. Generally, metacercariae that infect fish subsequently reach maturity in piscivorous birds [1, 2].

In fish, the metacercarial infection manifests primarily as black cysts (spots) within the skin, sub-epidermal tissue and in the fins [1]. Heavy

infections in young fish results oftenly in important mortalities, whereas older fish suffer from weight reduction, and muscle, liver and kidney degenerative changes.

The topic specificity of *Posthodiplostomum cuticola* and *Rossicotrema donicum* metacercariae and the disease frequency within the studied cyprinid populations are to be presented in the paper work.

2. Materials and methods

A total of 11 fish species were examined for Black spot disease, between 2003 and 2008: pike (*Esox lucius*), rudd (*Scardinius erythrophthalmus*), asp (*Aspius aspius*), Prussian carp (*Carassius gibelio*), grass carp (*Ctenopharyngodon idella*), silver carp (*Hypophthalmichthys molitrix*), zarte (*Vimba vimba*), roach (*Rutilus rutilus*), bream (*Abramis*

brama), catfish (*Silurus glanis*) and European perch (*Perca fluviatilis*). The study site was focused on the 4 natural complexes within the Danube Delta: Dunavat-Dranov, Razim-Sinoie, Sontea-Fortuna and Gorgova-Uzlina.

Clinical investigations were carried out on all the captured species. Metacercariae were found in 5 fish species: rudd (*Scardinius erythrophthalmus*), silver carp (*Hypophthalmichthys molitrix*), zarte (*Vimba vimba*), bream (*Abramis brama*) and European perch (*Perca fluviatilis*).

The metacercariae morphology was studied in light microscopy on fresh unstained sections.

3. Results and discussion

Rudd, carp, silver carp and zarte were found infected with *P. cuticola*, whereas perch harboured an infection with *R. donicum*. The

morphological differences of the cysts size and location were very discrete (figs 1 and 2).

In silver carp, the black spot disease was found constantly in the Dunavat-Dranov and Razim-Sinoie complexes during the entire study period. *P. cuticola* metacercariae were found in dermis (fig 3), fins and in the somatic muscle underneath the skin.

In rudd, which was captured from Gorgova-Uzlina, the distribution of the parasite was very similar to the one which was found in the silver carp.

In zarte and bream, the infection with *P. cuticola* metacercariae was confined to the Sontea-Fortuna area.

The infection with *R. donicum* metacercariae in perch was found in the Dunavat-Dranov and Rasim-Sinoie complexes. The metacercarial cysts were located only in the pectoral and caudal fins.




Figure 1. *P. cuticola* metacercariae in the pectoral fin; *Abramis brama*

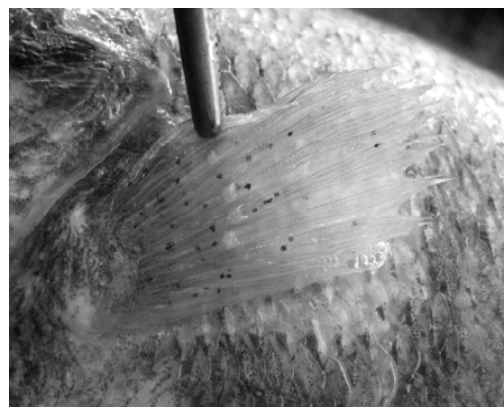


Figure 2. *R. donicum* metacercariae in the pectoral fin; *Perca fluviatilis*



Figure 3. *P. cuticola* metacercariae in *Hypophthalmichthys molitrix* – dermal location

Table 1. Estimation of the Black spot disease prevalence in *Scardinius erythrophthalmus* and *Hypophthalmichthys molitrix* caught in the Gorgova – Uzlina, Dunavat – Dranov and Razim – Sinoie natural complexes

Year	Analysed samples			<i>P. cuticola</i> metacercariae infection					
	Rudd	Silver carp		Rudd	Silver carp		Prevalence		
	Gorgova – Uzlina	Dunavat – Dranov	Razim – Sinoie	Gorgova – Uzlina	Dunavat – Dranov	Razim – Sinoie	Gorgova – Uzlina	Dunavat – Dranov	Razim – Sinoie
2003	155	270	194	40	83	57	25.81	30.74	29.38
2004	163	284	179	53	90	48	32.52	31.69	26.82
2005	142	267	205	35	79	53	24.65	29.59	25.85
2006	130	242	186	31	67	46	23.85	27.69	24.73
2007	148	305	160	44	102	51	29.73	33.44	31.88
2008	114	229	133	26	65	40	22.81	28.38	30.08
Overall analysed	852	1597	1057	229	486	295	26.56 ¹	30.26 ²	28.12 ³

¹26.56= the main value for estimating the prevalence

²30.26 = the main value for estimating the prevalence

³28.12 = the main value for estimating the prevalence

The black spot disease frequency in *Scardinius erythrophthalmus* and *Hypophthalmichthys molitrix* originating from the Gorgova-Uzlina, Dunavat-Dranov and Razim-Sinoie natural complexes was estimated between 2003 and 2008. According to the resulting data (table 1), the disease frequency varied among the two studied fish species from 0.2281 % in rudd (2008) to 0.3344 % in the silver carp caught in Dunavat-Dranov (2007). The main prevalences were 0.2656 % for rudd, 0.3026 % for the silver carp caught in Dunavat-Dranov, and 0.2812 % for the silver carp caught in Razim-Sinoie.

4. Conclusions

4.1. *P. cuticola* and *R. donicum* metacercariae produce both black cysts into the infected tissues of the hosts, although a slight difference in the size and location of the lesions according to the differing aethiology was noticed;

4.2. The lowest level of invasion with *P. cuticola* metacercariae was found in zarte and bream.

4.3. Infection with *R. donicum* was scarce, being found only in perch, restricted to the pectoral and caudal fins;

4.4. In both species, maximum prevalences of the disease frequency were very close to one another and they were acquired in different years: in rudd, 0.3252 % in the year 2004; in the silver carp caught in Dunavat-Dranov, 0.3344 % in the year 2007; in the silver carp caught in Razim-Sinoie, 0.3188 % in the year 2007;

4.5. Overall, by comparison with the other two situations, a maximum prevalence was found in the Silver carp caught in the Dunavat-Dranov natural complex, with a main percent of 0.3026 %.

References

1. Rolbiecki Leszek, Distribution of *Posthodiplostomum cuticola* (Normann, 1832) (Digenea; Diplostomidae) metacercariae in Cyprinids of the Vistula Lagoon, Arch. Pol. Fish., 2004, 12, Fasc. 1, 93-98
2. Paperna, I. And Dzikowski, R., Digenea (Phylum Platyhelminthes), Fish Diseases and Disorders Vol. 1: Protozoan and Metazoan Infections, second edition, P.T.K. Woo, Univ. of Guelph, Canada, 2006, pp. 345-390